




Lung 2023 Part 2

NAACCR 2023-2024 Monthly Webinar Series

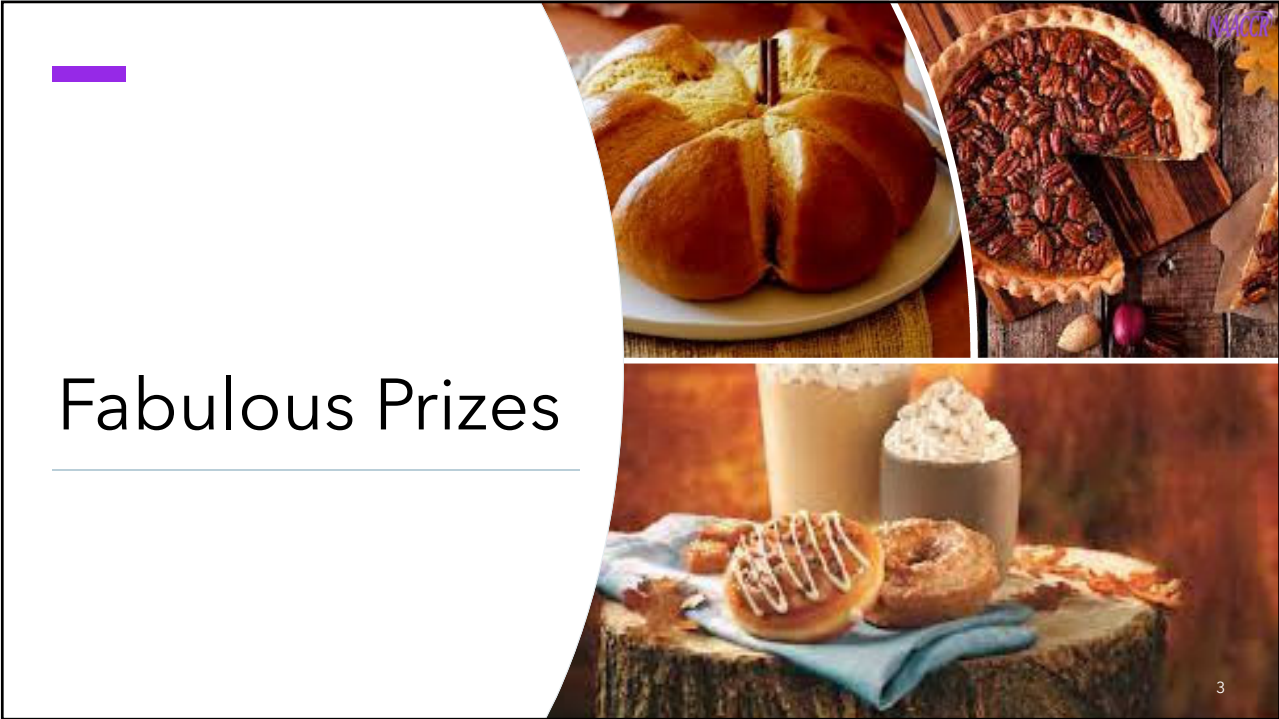Q&A

Please submit all questions concerning the webinar content through the Q&A panel.

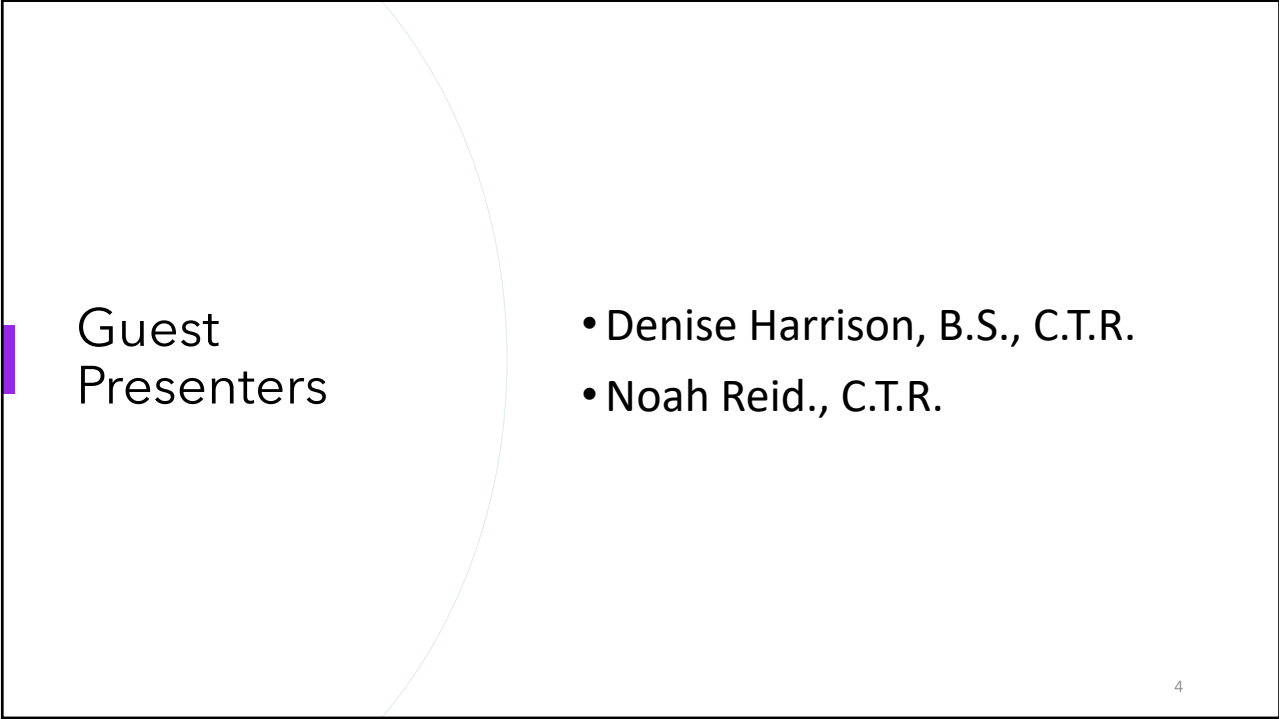
If you have participants watching this webinar at your site, please collect their names and emails.

We will be distributing a Q&A document in about one week. This document will fully answer questions asked during the webinar and will contain any corrections that we may discover after the webinar.

2



Fabulous Prizes



Guest Presenters

- Denise Harrison, B.S., C.T.R.
- Noah Reid., C.T.R.

Lung Part 2

NAACCR Webinar –Staging and SSDI

Denise Harrison, B.S., C.T.R.

Noah Reid., C.T.R.

Lung Histology

2020 LUL Lung resection:

Final dx: Well to Moderately differentiated adenocarcinoma, Lepidic 70%, Acinar 30%

Synoptic:

Histologic Type: Adenocarcinoma

Growth Patterns of Adenocarcinoma

- Lepidic: 70%

- Acinar: 30%

Assign Lepidic predominant adenoca 8250/3 per ASK

(New instruction will be added to 2024 updates)

Lung M Rules

Rule	Description	# Primaries
M1	Not possible to determine if there is a single tumor or multiple tumors	Single
M2	Single tumor	Single
M3	S/N-C tumors with site codes different at 2nd CXxx or 3rd CxXx	Multiple
M4	Subsequent tumor after clinically dz-free for > 3 years after dx OR recurrence	Multiple
M5	≥ 1 tumor small cell (8041) or variant AND another tumor non-small (8046) or variants	Multiple
M6	Sep/Non-Contig tumors ≥ 2 different subtypes in column 3 of Table 3	Multiple
M7	Synchronous Sep/Non-Contig tumors in the same lung in same row of Table 3	Single
M8	Sep/Non-Contig tumors in different rows Table 3 or one is combo code in Table 2 and the other is a code in Table 3	Multiple
M9	Simultaneous multiple tumors in BOTH lungs; SAME lung; or single tumor in 1 lung w/ multiple tumors in contralateral lung	Single
M10	In situ after invasive (in same lung)	Single
M11	Single tumor in EACH lung	Multiple
M12	Invasive tumor ≤ 60 days after in situ in same lung	Single
M13	Invasive > 60 days after in situ in same lung	Multiple
M14	None of the previous rules apply	Single

Lung Rules M6 - M8: Table 3

	Specific or NOS Histology Term and Code	Synonym of Specific or NOS	Subtype/variant of NOS and Code
1	<p>Sarcoma NOS 8800/3</p> <p>M7: SYNCHRONOUS on same row = SP (any of the following in the same row)</p> <p>Same Histology: Col. 1 + Col.2; Col. 2 + Col. 2 -or- Col. 1 + 1 sub/var Col. 3 -or- Col. 2 + 1 sub/var Col. 3</p>	<p>M6: Different subtypes = MP; Same or Different NOS</p> <p>M8: Different Rows = MP (any column)</p>	<p>Biphasic synovial sarcoma 9043/3</p> <p>Epithelioid cell synovial sarcoma 9042/3</p> <p>Pulmonary artery intimal sarcoma/low-grade malignant myxoid endobronchial tumor 9137/3</p> <p>Pulmonary myxoid sarcoma with EWSR1 - CREB1 translocation 8842/3</p> <p>Spindle cell synovial sarcoma 9041/3</p> <p>Synovial sarcoma 9040/3</p>
2	<p>Small cell carcinoma 8041/3</p> <p><i>Note 1:</i> This row applies to neuroendocrine tumors (NET).</p> <p><i>Note 2:</i> Large cell carcinoma with neuroendocrine differentiation lacks NE morphology and is coded as large cell carcinoma, not large cell neuroendocrine carcinoma.</p>	<p>Reserve cell carcinoma</p> <p>Round cell carcinoma</p> <p>SCLC</p> <p>Small cell carcinoma NOS</p> <p>Small cell neuroendocrine carcinoma</p>	<p>Atypical carcinoid 8249/3</p> <p>Combined small cell carcinoma 8045/3</p> <p>Typical carcinoid 8240/3</p> <p>Neuroendocrine carcinoma, NOS</p> <p>Well-differentiated neuroendocrine carcinoma</p>

of Primaries and Primary Site(s)

Rt lung w/ 4 synchronous invasive tumors; all limited to the lung

#1 RLL – Lg cell undifferentiated carcinoma (8012/3)

#2 RLL – 0.7 cm Acinar predominant adenoca (8551/3)

#3 RUL – 0.9 cm Mucinous adenoca (8253/3)

#4 RUL – 1 cm Adenoca, NOS (8140)

Apply the lung M rules:

#2 and #3 are different subtypes of Adenoca NOS – separate primaries per M6

#2 and #3 are on the same row as Adenoca, NOS – each is the same primary as Adenoca, NOS per M7

#1 is on a different row from #s 2-4 – different primary per M8

5

of Primaries and Primary Site

Rt lung w/ 4 synchronous invasive tumors; all limited to the lung

#1 RLL – Lg cell undifferentiated carcinoma (8012/3)

#2 RLL – 0.7 cm Acinar predominant adenoca (8551/3)

#3 RUL – 0.9 cm Mucinous adenoca (8253/3)

#4 RUL – 1 cm Adenoca, NOS (8140)

Abstract 3 primaries

Acinar predominant adenoca, RLL – C343

Mucinous adenoca, RUL – C341

Large cell undifferentiated carcinoma RLL – C343

The adenoca, NOS is the same primary as both the acinar predominant adenoca and the mucinous adenoca; disregard it when assigning EOD Primary Tumor for those primary tumors.

SEER*SINQ 2020004

6

Lung STR Rule M9

SINGLE primary when SIMULTANEOUS tumors:

- In BOTH lungs (multiple in Rt and multiple in Lt) OR
- In the SAME lung OR
- Single tumor in one lung; multiple tumors in the contralateral lung

Tumors may be combos of:

- In situ and invasive
- NOS and subtype/variant
- Cancer NOS 8000 or carcinoma NOS 8010 and any other histology

Code Multiple primaries ONLY when there is PROOF that one of the tumors is a **different histology**:

- Pathology proves different histology (should have STOPPED at M6 or M8)
- Physician states UNEQUIVOCALLY (no ambiguous terms such as probable) the tumors are different primaries

7

Lung Rule M9

11/22 CT Chest: 1.3 cm RUL nodule associated w/ mult nodular opacities all concerning for malignancy; persistent opacity LUL concerning for concomitant primary lung cancer

12/3 Bronchoscopy w/ EBUS: Lt lung WNL; Rt lung w/ extrinsic compression of RUL causing 90% obstruction

12/3 Path: Bx RUL and 4R LN: SqCC


12/7 PET: 1.4 cm FDG-avid primary malignancy RUL w/ multiple hypermetabolic RUL nodules and Rt hilar LNs consistent with mets; 10 mm spic nodule LUL suspicious for contralateral malignancy

Onc Note: T3 N2 M0 3B SqCC of RUL and synchronous stage 1 cancer in LUL given lack of Lt-sided LAD during EBUS

How many Primaries? 1 or 2?

2, based on unequivocal statement that the tumors are different primaries

8



General AJCC Staging

Poll # 1: cM versus pM

RUL bx: Small cell carcinoma
CT C/A/P: Bil low cervical and
bil bulky mediastinal LAD
Low cervical LN bx: Small cell
carcinoma
Treatment: Durvalumab,
Cisplatin, Etoposide

What is the correct **M** category?

- A. cM0
- B. cM1a
- C. pM0
- D. pM1a

Poll # 1: cM versus pM

RUL bx: Small cell carcinoma
CT C/A/P: Bil low cervical and bil bulky mediastinal LAD
Low cervical LN bx: Small cell carcinoma
Treatment: Durvalumab, Cisplatin, Etoposide

Answer: Choice **A, cM0**

Rationale:

- Low cervical LNs are RLNs for lung, and are included in N3
- The LN mets were microscopically proven; however, since these are RLNs, not distant LNs, assign cM0

11

Poll # 2: Incidental Finding at Surgery

PET/CT: 1.5 cm LUL nodule and second 2.4 cm nodule in posterior LUL both suspicious for malignancy
Bx LUL: Squamous cell carcinoma
FNA Stations 7 and 11 LNs: negative for malignancy
Clinical stage (med onc): T3N0(f)M0
LUL Lobectomy: 1.6 cm squamous cell carcinoma and 2.9 cm adenocarcinoma

What is the correct **clinical** staging for the **adenocarcinoma**?

- A. cT1c cN0 cM0 PSG 1A3
- B. cTX cNX cM0 PSG 99
- C. cT blank cN blank cM blank PSG 99

12

Poll # 2: Incidental Finding at Surgery

PET/CT: 1.5 cm LUL nodule and second 2.4 cm nodule in posterior LUL both suspicious for malignancy
Bx LUL: Squamous cell carcinoma
FNA Stations 7 and 11 LNs: negative for malignancy
Clinical stage (med onc): T3N0(f)M0
LUL Lobectomy: 1.6 cm squamous cell carcinoma and 2.9 cm adenocarcinoma

Answer: Choice C, cT blank cN blank cM blank PSG 99

Rationale:

- The adenocarcinoma was unknown during the clinical timeframe; therefore, leave the clinical TNM fields blank
- Don't go back in time to assign stage

13

Poll # 3: Physician vs. Registrar Assignment of TNM

PET/CT: RUL with 3.6 cm enlarging mixed GG and nodular lesion suspicious for lung cancer; no FDG uptake or significant enlargement of hilar or mediastinal LNs
Bx RUL: AIS
Treatment: SBRT due to comorbidities
Clinical stage (Surgeon): cT0 cNX cM0

What is the correct clinical staging?

- A. cT0 cNX cM0 PSG 99
- B. cTis cN0 cM0 PSG 0
- C. cT2a cN0 cM0 PSG 1B
- D. cT blank cN blank cM0 PSG 99

14

Poll # 3: Physician vs. Registrar Assignment of TNM

PET/CT: RUL with 3.6 cm enlarging mixed GG and nodular lesion suspicious for lung cancer; no FDG uptake or significant enlargement of hilar or mediastinal LNs
Bx RUL: AIS
Treatment: SBRT due to comorbidities
Clinical stage (Surgeon): cT0 cNX cM0

Answer: Choice c, **cT2a cN0 cM0 PSG 1B**

Rationale:

- cT2a: AIS has to be ≤ 3 cm per the definition of Tis; this one was 3.6 cm and was stated to be a mixed GG and nodular lesion; the bx potentially only identified a part of the mixed lesion
- cN0: the PET was negative for LN involvement

15

Poll # 4: Physician vs. Registrar Assignment of TNM

Clinical stage (Surgeon) based on CT chest: cT1c cN0 cM0
LUL Wedge Resection: Adenocarcinoma, solid predominant, G3, pT2a pNX
PET/CT (Post surgery): Mets in Rt hilar LN suspected
Cancer Conference: Pathological stage should be T2a N1 M0 Stage 2B, suggest adjuvant C/T

What is the correct pathological staging?

- A. pT2a cN1 cM0 PSG 2B
- B. pT2a pN1 cM0 PSG 2B
- C. pT2a pNX cM0 PSG 99
- D. pT2a pN blank cM0 PSG 99

16

Poll # 4: Physician vs. Registrar Assignment of TNM

Clinical stage (Surgeon) based on CT chest: cT1c cN0 cM0
LUL Wedge Resection: Adenocarcinoma, solid predominant, G3, pT2a pNX
PET/CT (Post surgery): Mets in Rt hilar LN suspected
Cancer Conference: Pathological stage should be T2a N1 M0 Stage 2b, suggest adjuvant C/T

Answer: Choice C, pT2a pNX cM0 PSG 99

Rationale:

- Physicians may assign stage with incomplete information (Chapter 1, AJCC), but the registrar does not record this.

Amin, Mahul B.; Gress, Donna M.; Meyer Vega, Laura R.; Edge, Stephen B.. AJCC Cancer Staging Manual, Eighth Edition (p. 25). American College of Surgeons. Kindle Edition.

17

Poll # 5: T Category

CT Chest: 2cm spic. nodule LUL; hilar lymphadenopathy
PET: (+) FDG uptake in LUL lung mass & hilar LN; **MRI Brain:** Negative
Scope: Bronchoscopy w/biopsy
Path: Poor diff adenocarcinoma, acinar predominant
Surgery: LUL lobectomy and mediastinal LN dissection
Path: 2.5 cm adenoca, G2, extending to visceral pleura (elastic stain performed); surg. margs neg; 2+/5 peribronchial LNs; all mediastinal LN negative

What is the correct pathological T?

- A. pT1
- B. pT1c
- C. pT2
- D. pT2a

18

Poll # 5: T Category

CT Chest: 2cm spic. nodule LUL; hilar lymphadenopathy
PET: (+) FDG uptake in LUL lung mass & hilar LN; **MRI Brain:** Negative
Scope: Bronchoscopy w/biopsy
Path: Poor diff adenocarcinoma, acinar predominant
Surgery: LUL lobectomy and mediastinal LN dissection
Path: 2.5 cm adenoca, G2, extending to visceral pleura (elastic stain performed); surg. margs neg; 2+/5 peribronchial LNs; all mediastinal LN negative

Answer: Choice D: **pT2a**

Rationale:

- If a T1 tumor (by size) involves the MSTB, extends to visceral pleura, or causes atelectasis or obstructive pneumonitis that extends to the hilar region, classify as T2a or T2b based on TS

Amin, Mahul B.; Gress, Donna M.; Meyer Vega, Laura R.; Edge, Stephen B.. AJCC Cancer Staging Manual, Eighth Edition (p. 447). American College of Surgeons. Kindle Edition.

19

Poll # 6: N Category

1/19/23: CT Chest: 4.2cm spic. nodule LUL; enlarged Lt hilar LNs suspicious for mets
1/21/23 PET/CT: 4.5 cm LUL mass and Lt hilar LNs with (+) FDG uptake; **MRI Brain:** Negative
Surgery: LUL wedge and mediastinal LND
Path: 4.6 cm adenoca, G2; 0+/9 LNs (stations 5, 6, 7, 8,9) surg. margs neg; pT2bN0
Thoracic TB: Hilar LNs not approached in the surgery; suspect N1 dz; RT to LNs suggested

What is the correct pathological N?

- A. **pNX**
- B. **pNblank**
- C. **pN0**
- D. **pN1**

20

Poll # 6: N Category

1/19/23: CT Chest: 4.2cm spic. nodule LUL; enlarged Lt hilar LNs suspicious for mets

1/21/23 PET/CT: 4.5 cm LUL mass and Lt hilar LNs with (+) FDG uptake hilar LN;

MRI Brain: Negative

2/17/23 Surgery: LUL wedge resection and mediastinal LND

Path: 4.6 cm adenoca, G2; 0+/9 LNs (stations 5, 6, 7, 8, 9) surg. margs neg; pT2bN0

Thoracic TB: Hilar LNs not approached in the surgery; suspect N1 dz; RT to LNs suggested


Answer: Choice D: **pN1**

Rationale:

- At least 1 RLN was microscopically assessed AND the criterion for pT (resection) was met; include the involvement of the hilar LNs in the pathological N

Amin, Mahul B.; Gress, Donna M.; Meyer Vega, Laura R.; Edge, Stephen B.. AJCC Cancer Staging Manual, Eighth Edition (p. 20). American College of Surgeons. Kindle Edition.

21



Adenocarcinoma Spectrum

4 Stages of Lung Adenocarcinoma (The Adenocarcinoma Spectrum)

PREINVASIVE Stages

1. Atypical adenomatous hyperplasia (AAH)
 - Earliest detectable preinvasive lesion
 - CT appearance is pure GGN, usually < 5mm
 - Cells creep along alveolar ducts in “lepidic” pattern
2. Adenocarcinoma in situ (AIS)
 - Solid < 3 cm lesion w/ pure lepidic growth along alveolar ducts
 - Majority are non-mucinous


23

4 Stages of Lung Adenocarcinoma, continued (The Adenocarcinoma Spectrum)

INVASIVE Stages

3. Minimally invasive adenocarcinoma (MIA)
 - <3cm lesion w/< 5 mm invasive area
 - Invasive focus defined when
 - Histo is not lepidic adenoca
 - Stroma infiltrated by tumor cells
4. Adenocarcinoma
 - > 5 mm invasive focus of cell type other than lepidic in presence of myofibroblastic stroma associated w/ tumor cell infiltration, WITH
 - invasion of
 - pleura
 - blood vessels or lymphatics
 - OR when tumor necrosis is present

24



Vocabulary

Synchronous Primary Cancers

TIMING: Tumors occur in the **SAME** organ (including paired organs)

- ≤4 months apart -OR-
- Are ID'd during surgery for the 1st cancer if that surgery is part of the planned FCOT

MULTIPLE SYNCHRONOUS TUMORS are cancers of the **SAME histology** that occur in one organ

SYNCHRONOUS PRIMARY TUMORS IN A: SINGLE ORGAN

- Assign T to highest T category and use the (m) suffix [**invasive** cancers only]

PAIRED ORGAN

- Staged as separate cancers (examples: breast, lung, and kidney)
- Exception: multiplicity is included in the T category for thyroid, liver, and ovary; do **NOT** stage tumors separately

Synchronous Tumors (Separate Primary Tumors) AJCC Tables 36.3 (Clinical) and 36.7 (Pathological)

- **Second Primary Tumors if:**
 - Histology is different (c – presumed different; p – clearly different)
 - Comprehensive histologic assessment is different (p)
 - Breakpoints (via comparative genomic hybridization) are different (c/p)
 - SqCC arising from CIS (p)
- **Favor Separate Tumor w/ clinical features if:**
 - **Different** clinical features (radiographic appearance, metabolic uptake, rates of growth)
 - **Different** biomarker pattern (c/p)
 - **Lacking** nodal and or systemic mets (c/p)

Intrapulmonary Mets (Separate Tumor Nodules)

Clinical (AJCC Table 36.4):

- Solid lung cancer **W/**
 - Separate tumor nodule(s) w/ a similar solid appearance **AND**
 - W/ presumed matching histo appearance
 - Bx of all lesions **NOT** required
 - Applies regardless of extrathoracic mets

Pathological (AJCC Table 36.8):

- Separate tumor nodules w/ a similar histologic appearance to the primary lung cancer

Clinical and Pathological (AJCC Tables 36.4 and 36.8): PLUS they are **NOT** judged to be

- Synchronous primary lung cancers -OR-
- Multifocal LPA, MIA, or AIS -OR-
- Pneumonic-type lung CA

Criterion	2nd Primary Tumor(s)	Single Tumor Source (Related Tumors)
		Solid tumor w/ STN(s) w/
Histology	Different (c/p)	Same (c/p)
Breakpoints (via comparative genomic hybridization)	Different	Exactly matching (c/p)
Comprehensive histologic appearance	Presumed different (c) / Clearly Different (p)	Presumed matching (c) (comprehensive requires resection)
		and NOT judged to be:
		Synchronous cancers (c/p)
		or multifocal GG/L lung CA (c/p)
		or pneumonic-type lung CA (c/p)
	SqCC arising from CIS (p)	


Synchronous Tumors vs. Separate Tumor Nodules

25

Criterion	2nd Primary Tumor	Single Tumor Source
		Solid tumor w/ STN(s) w/
Clinical features	Different (c/p)	Same (c/p)
Radiographic appearance	Different (c/p)	Same (c/p)
Metabolic uptake	Different (c/p)	Same (c/p)
Rate of growth	Different (c/p)	Same (c/p)
Biomarker pattern (driver gene mutations)	Different (c/p)	Similar (c/p)
Nodal or systemic mets	Absent (c/p)	Significant (c/p)

Favor Synchronous Tumors vs. Separate Tumor Nodules

26



Separate Tumor
Nodules: T3 vs
T4 vs M1a

Separate Tumor Nodules: Intrathoracic and Extrathoracic Metastases

- T1** Based solely on size

- T2** Size or extension

- T3** Size, extension or satellite nodules in same lobe

- T4** Size, extension or separate tumor nodule(s) in different lobe of ipsilateral lung

- M1** Contralateral intrathoracic vs. single extrathoracic vs. multiple extrathoracic metastasis

Presentations of Multiple Lung Tumors

Multifocal GG/L Adenocarcinoma

- ✓ **Opacity:** Descriptive term referring to a hazy area of increased attenuation in lung
 - ✓ **Nodule:** Circumscribed area of increased pulm attenuation w/ preservation of bronch/vasc marg
 - ✓ Non-specific, etiology includes infection, chronic interstitial disease and acute alveolar disease
 - ✓ Can be malignancy, hyperplasia, fibrosis, aspergillosis, or focal pulm hemorrhages
 - ✓ T classification of multifocal GG/L adenocarcinoma is based on size or extent of invasion
-

Separate tumor nodules

- ✓ Presents as single tumor (often solid or spiculated) w/ separate associated solid nodules
- ✓ Resection path must show distinct masses w/ same morph (must be based on comprehensive histo assessment)
- ✓ Location of separate tumor nodules reflected in T or M categories (T3 vs. T4 vs. M1a)

Presentations of Multiple Lung Tumors, cont.

Pneumonic-Type Adenoca

- ✓ Presents as a single tumor w/ diffuse areas of GG and consolidation
 - ✓ Histology is uniform throughout (commonly mucinous adenoca)
 - ✓ Location of separate tumor nodules is reflected in T or M categories (T3 vs. T4 vs. M1a)
-

Separate Primary Lung Cancers

- ✓ Tumors are not related to each other
- ✓ 2+ masses w/ characteristics of lung cancer on imaging
- ✓ Distinct histo or morph on resection path (must be based on comprehensive histo assessment)
- ✓ Each tumor is staged independently


See AJCC Lung Chapter, pages438-439 for in-depth definitions of all 4 patterns

Separate Tumor Nodules?

★ If pathologist notes mult foci or nodules but assigns a lower T category (<T3), do not include as intrapulm mets and use (m) suffix w/ highest T category based on size or extension
☞ SSDI would be coded to 0 (no separate tumor nodules)

★ If unclear whether separate tumor nodules (intrapulm mets) or synchronous tumors, assign Tblank

(see AJCC Lung Chapter Tables 36.3 and 36.4 for clin, 36.7 and 36.8 for path)



When to Use
T(m) Suffix

When to Use T(m) Suffix


📎 Multiple synchronous tumors that are abstracted as a single primary, OR multifocal lung adenoca with GG/L features

📎 Based on AJCC definitions in Lung chapter table 36.6

📎 When (m) suffix is used, assign SSDI for separate tumor nodules to code 0 because they are not considered separate tumor nodules/intrapulm mets

📎 For multifocal GG/L adenoca, (m) applies regardless of the location of the lesions (same ipsi, different ipsi, different lung)

📎 Accounts for add'l involved tumors not reflected in T category, to document greater tumor burden than T category indicates



**SSDI: Separate
Tumor Nodules**

SSDI: Separate Tumor Nodules

Code	Definition
0	Single tumor or >1 nodule w/ different histo
1	Separate nodules, same lobe
2	Separate nodules, different ipsilateral lobe
3	Separate nodules, same and different ipsilateral lobes
4	Separate nodules ipsilateral lung, unk if same or different lobe
7	Multiple nodules present, not classifiable based on notes 3 or 4
8	Not applicable
9	Not documented, not assessed, or unknown

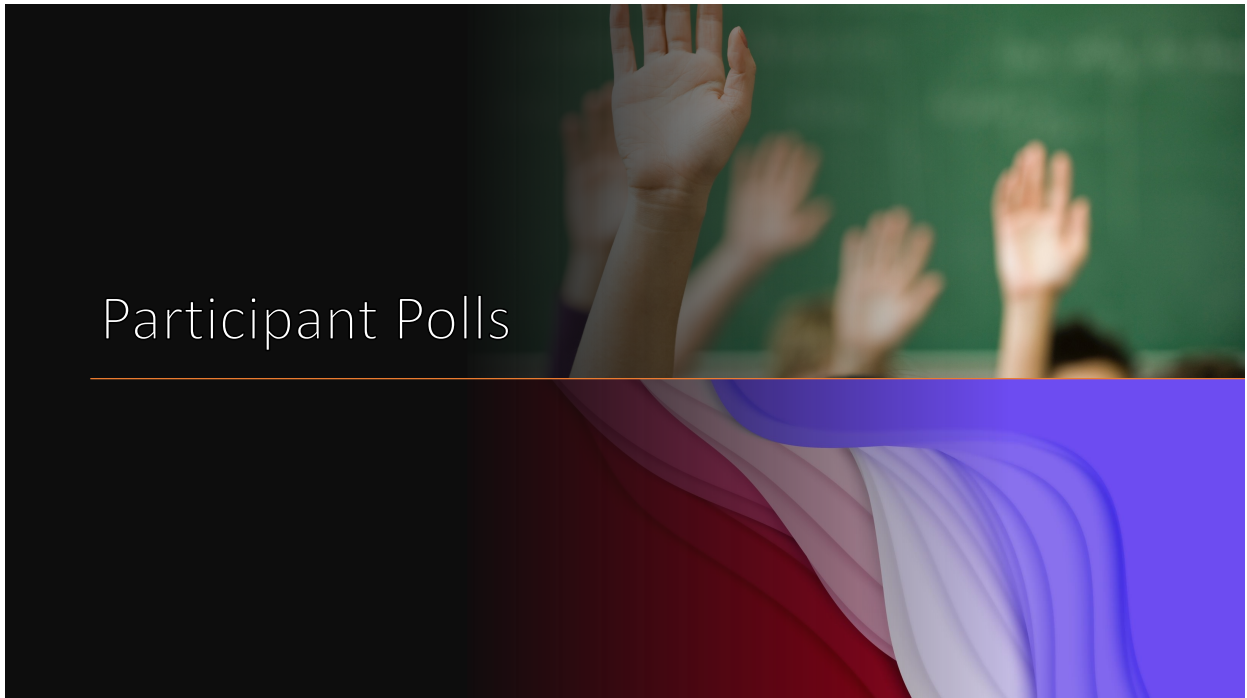SSDI: Separate Tumor Nodules

- ✎ Nodules can be identified by imaging studies or pathology reports
- ✎ Can use physician's statement if there is no other information
- ✎ Per note 4, use code 0 (no separate nodules) when separate nodules are identified but characterized as:
 - Synchronous primary tumors
 - Multifocal GG/L adenoca
 - Diffuse pneumonic adenoca
- ✎ Per note 5, "Synchronous" describes appearance in time relative to primary tumor. Don't code solely based on use of "synchronous"
- ✎ If separate nodules described as "metachronous," could be evidence of progression, don't code in SSDI separate tumor nodules if that's the case

SSDI: Separate Tumor Nodules

- ✎ Use code 7 (mult nodules present, NOS) when mult nodules are present but terminology not listed in Note 4 and you have no further information
 - Example: CT chest: LUL postobstructive pneumonia related to obstructing malignant suprahilar mass. Two additional tumor nodules in LUL.
 - In this case do not use the other tumor nodules to determine the T category or extent of disease (i.e. EOD or SS)
- ✎ If relevant imaging or resection path don't mention separate tumor nodules, assume there are none present and assign code 0
- ✎ Assign code 9 (Not documented, not assessed, or unknown) when there is no resection or relevant imaging

Participant Polls



Participant Poll #7: Scenario

5/3/22 CT Chest

15mm GGN superior RLL larger since last study, peripheral GGO superior RLL 9.4mm, 3.3mm GGN RLL, 3mm RML nodule, no pleur eff or LAD

Impression: Mult RLL and RML nodules and GGOs, dominant superior RLL opacity increased in size

5/7/22 Pulmonology Note

Pt presents for f/u of CT showing GGN increased in size from previous study. Significant chance opacity represents CIS; recommend resection.

5/20/22 RLL Super Segmentectomy

Adenoca w/ predominant lepidic pattern, 1.4cm dominant mass confined to lung w/ multicentric, multifocal adenoca (4-5 nodules) in same lobe ranging from 0.4 – 0.8cm – all similar morph, VPI/LVI neg, marg neg, no LNs sampled

What is the path T and Separate Tumor Nodules SSDI?

- A. pT3, SSDI 1
- B. pT4(m), SSDI 2
- C. pT1b(m), SSDI 0
- D. pT1b, SSDI 7

Participant Poll #7: Rationale

pT: pT1b(m)

Rationale: Per AJCC Lung Chapter, multifocal lung adenoCAs w/ GG/L features are classified by highest T using the (m) suffix (in this case the path report also stated this is a T1b(m))

SSDI: 0 (No separate tumor nodules)

Rationale: Per note 4, use code 0 (no separate tumor nodules) when characterized as multifocal lung adenoca w/ GG/L features

Participant Poll #8: Scenario

5/6/23 CT Chest

Mult susp L lung lesions, lgst in posterior LLL measures 4.9cm, no LAD and no significant findings in contralateral lung

5/12/23 PET

Hypermetabolic 6.1cm posterior LLL lung lesion w/ at least 3 other lesions scattered throughout LLL, add'l 1cm moderately hypermetabolic LUL lesion is identified, susp for malig

6/14/23 LLL Lobectomy/LUL Wedge

3 LLL lesions w/ invas adenoca w/ dominant 5.5 cm mass in posterior aspect; 1.2cm invas adenoca in posterior LUL, overall findings c/w separate tumor nodules in same and different lobes, 0/7 LNs+, marg neg, no VPI/LVI

What is the T category and Separate Tumor Nodules SSDI?

- A. pT3(m) SSDI 0
- B. pT4, SSDI 3
- C. pT4(m), SSDI 0
- D. pT3, SSDI 2

Participant Poll #8: Rationale

pT: pT4
Rationale: Separate tumor nodules in same and different ipsilateral lobes

SSDI: 3 (Separate tumor nodules, same and different ipsilateral lobes)
Rationale: Patient has multiple separate tumor nodules in the same lobe, but there is also a separate tumor nodule in the LUL (different ipsilateral lobe) and there is a statement from the pathologist that these are c/w separate tumor nodules in the same and different ipsilateral lobes

Code the highest T category based on the information we have, which in this case is separate tumor nodules in a different ipsilateral lobe

Participant Poll #9: Scenario

6/30/23 CT Chest

4.6cm LUL spiculated mass susp for primary adenoca, dominant 2.9cm RUL lesion w/ mult spiculated RUL nodules - most likely contralateral intrapulm mets, both dominant lesions larger since previous study, new 0.8cm RUL GGN, stable 1.2cm RLL area of GGO, 8mm R high paratracheal LN and 7mm L prevascular LN susp for LN mets

7/4/23 LUL Mass Biopsy: PD adenoca c/w lung origin

R Paratracheal LN Biopsy: Adenoca of lung origin

7/8/23 PET

4.8cm hypermetabolic LUL mass w/ mult RUL nodules (lgst = 2.5cm) c/w contralateral mets, b/l dominant masses have similar appearance, w/ FDG-avid LNs in R paratracheal and L prevascular regions c/w known LN mets

What is the clin TNM and Separate Tumor Nodules SSDI?

- A. cT2b cN3 cM1a, SSDI 0
- B. Synchronous Tumors
- C. cT2b pN3 cM1a, SSDI 0
- D. cT3 pN2 cM1a, SSDI 1

Participant Poll #9: Rationale

Stage: cT2b cN3 cM1a cStg IVA

Rationale: cT2b based on size, cN3 based on involved R paratracheal LN, M1a based on separate tumor nodules in contralateral lung w/ MD statement of contralateral lung mets

SSDI: 0 (No separate tumor nodules)

Rationale: No separate tumor nodules noted anywhere in ipsilateral lung

Although contralateral lung nodules are not histologically confirmed to be malignant, per AJCC Lung Chapter (tables 36.3 and 36.4) this meets criteria for consideration as a separate tumor nodule:

- ✓ There is a solid lung cancer and a separate nodule with a similar solid radiographic appearance with presumed matching histologic appearance
- ✓ Similar growth patterns
- ✓ Significant nodal or systemic mets
- ✓ Lesions are not judged to be synchronous primaries
- ✓ Lesions are not multifocal GG/L lung cancer

Participant Poll #10: Scenario

4/14/23 PET

Pulmonary lesions with moderate to intense hypermetabolism in R lung w/ 1.7cm and 1cm RLL masses, as well as 1.3cm RML mass susp for primary lung ca vs. lung mets

4/30/23 RLL/RML Bilobectomy

Multifocal invas adenoca involving RLL and RML (see micro description), 0/6 LNs+, marg neg, LVI/VPI neg

Microscopic Description

2.6cm acinar predominant adenoca that crosses the fissure from RLL into RML

1.4cm mucinous adenoca in RLL

Is this case assigned as:

- A. pT1c(m) pN0 cM0, SSDI 0
- B. pT3 pN0 cM0, SSDI 1
- C. Multiple Primaries
- D. pT4 pN0 cM0, SSDI 2

Participant Poll #10: Rationale

Answer: Multiple primaries
Acinar predominant adenoca assigned pT2a pN0 cM0 pStg IB
Mucinous adenoca assigned pT1b pN0 cM0 IA2

Rationale

Per Rule M6 of STR these are synchronous tumors that are abstracted separately because they are different subtypes/variants

The acinar predominant adenoca is T1c by size, but it is assigned pT2a because it extends into the adjacent lobe (see AJCC Lung table 36.12)

Mucinous T is assigned based on size alone

SSDI is coded as 0 for both as there are no separate tumor nodules

Poll # 11: T, (m) Suffix, and STN SSDI

LUL Wedge Resection: Invasive adenocarcinoma, Multifocal w/ 4 separate foci (0.9 mm, 0.7 mm, 0.5 mm, and 0.3 mm), margs neg; Level 5 LNs: 0+3 LNs, Level 7 LNs: fibroconnective and adipose tissue w/ scant lymphoid aggregate, pT1a(m)N0.

Note: Assignment of T category is based on the size of the largest focus AND checked the (m)

What is the correct T category and Separate Tumor Nodule SSDI?

- A. pT1a; 0
- B. pT1a(m); 0
- C. pT3; 1
- D. pT3(m); 1

51

Poll # 11: T, (m) Suffix, and STN SSDI

LUL Wedge Resection: Invasive adenocarcinoma, 4 separate foci (0.9 mm, 0.7 mm, 0.5 mm, and 0.3 mm), margs neg; Level 5 LNs: 0+3 LNs, Level 7 LNs: fibroconnective and adipose tissue w/ scant lymphoid aggregate; pT1a(4) N0
Note: Assignment of T category is based on the size of the largest focus AND checked the (m)

Answer: Choice **b, pT1a(m); 0**

Rationale:

- Since the pathologist assigned pT1a, (s)he is counting these as synchronous tumors, not separate tumor nodules (intrapulmonary mets)
- Synchronous tumors, but related to one another
- (m) suffix communicates tumor burden
- SSDI is 0 for no separate tumor nodules

52

Poll # 12: T, (m) Suffix

LUL lobectomy: 3.3 cm invasive adenoca, acinar predominant, G2, pT2a pN0. **LLL wedge resection:** 0.8 cm invasive adenoca, acinar predominant w/ focal papillary morphology, G2, pT1b pN0; 0+/6 LNs from levels 5 (3 LNs), 6 (1 LN), & 7 (2 LNs); margs neg, no visceral pleural invasion.

Op note: Mass in LUL and nodule in LLL; the tumors appear slightly different and likely represent synchronous primaries

What is the correct pathological **T category**?

- A. pT2a
- B. pT2a(m)
- C. pT4
- D. pT4(m)

53

Poll # 12: T, (m) Suffix

LUL lobectomy: 3.3 cm invasive adenoca, acinar predominant, G2, pT2a pN0. **LLL wedge resection:** 0.8 cm invasive adenoca, acinar predominant w/ focal papillary morphology, G2, pT1b pN0; 0+/6 LNs from levels 5 (3 LNs), 6 (1 LN), & 7 (2 LNs); margs neg, no visceral pleural invasion.

Op note: Mass in LUL and nodule in LLL; the tumors appear slightly different and likely represent synchronous primaries

Answer: Choice B, **pT2a(m)**

Rationale:

- The surgeon stated the tumors appeared slightly different and likely represent synchronous primaries and the pathologist also staged them as separate primaries
- Assign the T category based on the tumor with the largest T
- Use the (m) suffix for synchronous primary tumors to indicate tumor burden
 - AJCC defines these as synchronous primary tumors; our STR classify these as a single primary

54

Poll # 13: T, (m) Suffix

CT Chest: 2 lesions w/in LUL, 2 cm w/ GG component and 2.1 cm w/ GG component, both suspected to be bronchogenic malignancy; no regional adenopathy
LUL lobectomy and LND: Mod diff acinar predominant adenoca (85% acinar, 15% lepidic), pT1b; synchronous mod-well diff adenoca (60% acinar, 40% lepidic), pT1b; 0+/14 LNs, pN0; margs neg.
Note: (m) descriptor checked on synoptic report

What is the correct pathological **T category**?

- A. pT1b
- B. pT1b(m)
- C. pT3
- D. pT3(m)

55

Poll # 13: T, (m) Suffix

CT Chest: 2 lesions w/in LUL, 2 cm w/ GG component and 2.1 cm w/ GG component, both suspected to be bronchogenic malignancy; no regional adenopathy
LUL lobectomy and LND: Mod diff acinar predominant adenoca (85% acinar, 15% lepidic), pT1b; synchronous mod-well diff adenoca (60% acinar, 40% lepidic), pT1b; 0+/14 LNs, pN0; margs neg.
Note: (m) descriptor checked on synoptic report

Answer: Choice B, **pT1b(m)**

Rationale:

- The pathologist stated the tumors were synchronous and staged them separately
- Assign the T category based on the tumor with the largest T
- Use the (m) suffix for synchronous tumors to indicate tumor burden
 - AJCC defines these as synchronous primary tumors; our STR return a single primary

56

Poll # 14: T, (m) Suffix

12/29/20 CT Chest: 2 GGN (RUL and RLL) noted; 04/19/23 PET: GGNs in RUL and RLL suspicious for a low grade primary lung malignancy; 09/12/23 CT: 1.7cm sub-solid (GG) nodule in posterior RUL and 1.3cm GGN in superior segment of RLL, both are "concerning for malignancy".

Surgery: 10/22/23 RUL wedge and RLL wedge w/ 2 LNs.

Path: Inv well diff adenocarcinoma, lepidic predominant, in RUL (2.2cm) and RLL (1.2cm); No visceral pleura invasion; LVI(-); surg margins(-); 0+/2 LNs.

What is the correct pathological T?

- A. pT1b
- B. pT1b(m)
- C. pT4
- D. pT4(m)

57

Poll # 14: T, (m) Suffix

12/29/20 CT Chest: 2 GGN (RUL and RLL) noted; 04/19/23 PET: GGN in RUL and RLL suspicious for a low grade primary lung malignancy; 09/12/23 CT: 1.7cm sub-solid (GG) nodule in posterior RUL and 1.3cm GGN in superior segment of RLL, both are "concerning for malignancy".

Surgery: 10/22/23 RUL wedge and RLL wedge w/ 2 LNs.

Path: Inv well diff adenocarcinoma, lepidic predominant, in RUL (2.2cm) and RLL (1.2cm); No visceral pleura invasion; LVI(-); surg margins(-); 0+/2 LNs.


Answer: Choice B: **pT1b(m)**

Rationale:

- Classify GGN according to the tumor with the highest T and use the (m) suffix regardless of the location of the lesions (same lobe, different lobe, or contralateral lobe)

Amin, Mahul B.; Gress, Donna M.; Meyer Vega, Laura R.; Edge, Stephen B., AJCC Cancer Staging Manual, Eighth Edition (p. 25). American College of Surgeons. Kindle Edition.

58



EOD and SS 2018

SS18 0-1 and EOD Primary Tumor 000-400, 600

EOD	SS2018	Description
000	0	In situ, intraepithelial, noninvasive Adenocarcinoma in situ (AIS): adenocarcinoma with pure lepidic pattern, ≤ 3 cm Squamous cell carcinoma in situ (SCIS)
100	1	Minimally invasive adenocarcinoma; Adenocarcinoma tumor W/ predominantly lepidic pattern (AIS) ≤ 3 cm W/ invasive component ≤ 5 mm in greatest dimension
200		Superficial tumor, WITH invasive component limited to bronchial wall W/ or W/OUT proximal extension to main stem bronchus (these types of tumors are uncommon)
300		Localized only (localized, NOS) Confined to lung, NOS
400		Adjacent ipsilateral lobe Confined to hilus
		Main stem bronchus, NOS (W/OUT involvement of carina) Including extension from other part of lung
600		Confined to carina

Poll # 15: EOD Primary Tumor and SS2018

Imaging:

12/29/2020 CT Chest: Two "ground-glass" nodules (RUL and RLL) noted.

04/19/2023 PET: Suspicious for a low grade primary lung malignancy.

09/12/2023 CT: 1.7cm sub-solid (ground-glass) nodule in posterior RUL and 1.3cm ground-glass nodule in superior segment of RLL, both are "concerning for malignancy".

Surgery: 10/22/2023 RUL wedge and RLL wedge w/two LNs.

Path: Inv well diff Adenoca, with predominant lepidic pattern (adenocarcinoma, lepidic predominant), in RUL (2.2cm) and RLL (1.2cm); No visceral pleura invasion; LVI(-); surg margins(-); 0+/2 LNs.

How would we assign SS2018 and EOD Primary Tumor?

- A. SS 1, EOD 100
- B. SS 1, EOD 200
- C. SS 1, EOD 300

61

Poll # 15: EOD Primary Tumor and SS2018

Imaging:

12/29/2020 CT Chest: Two "ground-glass" nodules (RUL and RLL) noted.

04/19/2023 PET: Suspicious for a low grade primary lung malignancy.

09/12/2023 CT: 1.7cm sub-solid (ground-glass) nodule in posterior RUL and 1.3cm ground-glass nodule in superior segment of RLL, both are "concerning for malignancy".

Surgery: 10/22/2023 RUL wedge and RLL wedge w/two LNs.

Path: Inv well diff Adenoca, with predominant lepidic pattern (adenocarcinoma, lepidic predominant), in RUL (2.2cm) and RLL (1.2cm); No visceral pleura invasion; LVI(-); surg margins(-); 0+/2 LNs.

Answer: Choice C: **SS 1, EOD 300**

Rationale:

Note 3 SS: LPA are not separate tumor nodules; do not include in EOD assignment

Note 3 EOD: If predominantly **lepidic pattern** is present and the size of the invasive component is unknown, see code 300

62

EOD Primary Tumor

Rt lung w/ 4 synchronous invasive tumors; all limited to the lung

- #1 RLL – Lg cell undifferentiated carcinoma (8012/3)
- #2 RLL – 0.7 cm Acinar predominant adenoca (8551/3)
- #3 RUL – 0.9 cm Mucinous adenoca (8253/3)
- #4 RUL – 1 cm Adenoca, NOS (8140)

3 primaries (from slides 5 and 6)

Acinar predominant adenoca, RLL - C343
Mucinous adenoca, RUL – C341
Large cell undifferentiated carcinoma – C343

The adenoca, NOS is the same primary as both the acinar predominant adenoca and the mucinous adenoca; disregard it when assigning EOD Primary Tumor for those primary tumors.

SEER*SINQ 2020004

63

EOD Primary Tumor; SS 2018

Rt lung w/ 4 synchronous invasive tumors; all limited to the lung

- #1 RLL – Lg cell undifferentiated carcinoma (8012/3)
- #2 RLL – 0.7 cm Acinar predominant adenoca (8551/3)
- #3 RUL – 0.9 cm Mucinous adenoca (8253/3)
- #4 RUL – 1 cm Adenoca, NOS (8140)

3 primaries (from slides 5 and 6)

Acinar predominant adenoca, RLL – C343
EOD 300; SS 1
Mucinous adenoca, RUL – C341
EOD 300; SS 1
Large cell undifferentiated carcinoma – C343
EOD 300; SS 1

Disregard the adenoca, NOS when assigning EOD Primary Tumor for the mucinous and acinar predominant primaries: SEER*SINQ 2020004

64

SS18 and EOD Regional Nodes

	EOD	SS2018	EOD	SS2018
IPSI	300	3	400	3
BI/C	700	7	700	7
Bronchial			Carinal (tracheobronchial) (tracheal bifurcation)	
Peri/parabronchial			Mediastinal	
Hilar (bronchopulmonary) (proximal lobar) (pulmonary root)			Anterior	Superior
Intrapulmonary			Aortic (above diaphragm), NOS	Paratracheal (Lt, Rt, upper, low, NOS)
Interlobar			Peri/para-aortic, NOS	Azgos (lower paratracheal)
Lobar			Ascending aorta (phrenic)	Prevascular
Segmental			Subaortic (A-P window)	Retrotracheal
Subsegmental			Inferior	Periesophageal
			Paraesophageal	Pericardial
			Pulmonary ligament	Precarinal
			Subcarinal	Pretracheal, NOS
			Posterior (tracheoesophageal)	
IPSI/BI/CONTRA (EOD – 600; SS18 – 7)				
Low cervical; Proximal root; Scalene (inferior deep cervical); Sternal notch; Supraclavicular (transverse cervical)				

65



Questions?



Questions??

Fabulous Prizes

6

Coming UP...

Afternoon session is on
11/1/23

- Radiation and Radiology
 - Wilson Apollo
- Liver and Bile Ducts
 - Denise Harrison, BS, CTR



CE Certificate Quiz/Survey

CE Phrase

Link





Thank you!!!
