

Case Scenarios

CASE 1

64-yr-old male w/ h/o HTN, DMII, who presented w/ cough, GERD. Pt reports dysphagia with solid foods, resulting in regurgitation. Former heavy smoker. Social etoh. +FHX: Sister w/ gastric cancer.

Imaging:

6/17/22 @ YYY Hospital: EUS= 2.4 x 1.8 cm ill-defined mass @ EG junction.

6/20/22 @ YYY Hospital: CT chest= distention/dilation @ distal esophagus. No prominent lymphadenopathy noted.

6/28/22 @ YYY Hospital: Upper GI endoscopy= Z-line irregular, 35 cm from incisors. Biopsied. Sonographic evidence of extension into muscularis propria, but not beyond, Nodular mucosa in the gastric body. No gross lesion in the visualized duodenum.

7/20/22 @ YYY Hospital: PET/CT= increased FDG avidity in distal esophagus, GE junction. Small FDG avid upper abdominal lymph node consistent with metastatic disease.

Pathology:

6/28/22 @ YYY Hospital: GE Junction Fine Needle Biopsy= poorly differentiated adenocarcinoma, with invasion into muscle. FNA= positive for malignant cells, favor adenocarcinoma.

Positive= CKY

Negative= CK20, CDX-2, p40. HER IHC= 1+, negative. MMR intact.

Treatment:

8/20/22 @ ZZZ Hospital: Carboplatin + paclitaxel.

Radiation Therapy Treatment Summary

SUMMARY OF RADIATION FIELDS (ZZZ Hospital)

Course: 1

Treatment Site	Ref. ID	Energy	Dose/Fx (cGy)	#Fx	Total Dose (cGy)	Start Date	End Date	Elapsed Days
Esophagus /LN	Esophagus/LN	6X	180	19 / 19	3,420	8/15/2022	9/13/2022	29
Eso/LN_boost	Eso/LN boost	6X	180	9 / 9	1,620	9/15/2022	9/28/2022	13

Course: 1

Treatment Site: Esophagus/LN

Ref. ID: Esophagus/LN

Energy: 6X

Dose/Fx (cGy): 180

#Fx: 19 / 19

Dose Correction (cGy): 0

Total Dose (cGy): 3,420

Start Date: 8/15/2022

End Date: 9/13/2022

Elapsed Days: 29

Course: 1

Treatment Site: Eso/LN_boost

Ref. ID: Eso/LN_boost

Energy: 6X

Dose/Fx (cGy): 180

#Fx: 9 / 9

Dose Correction (cGy): 0

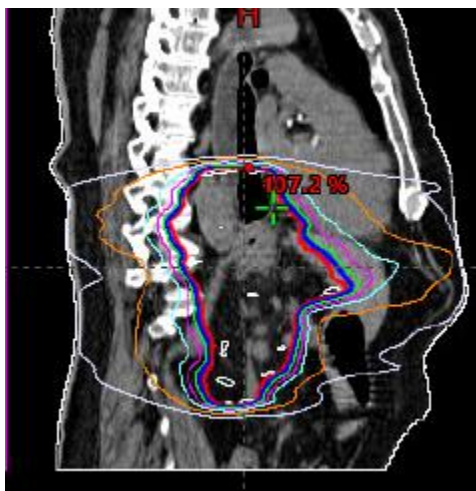
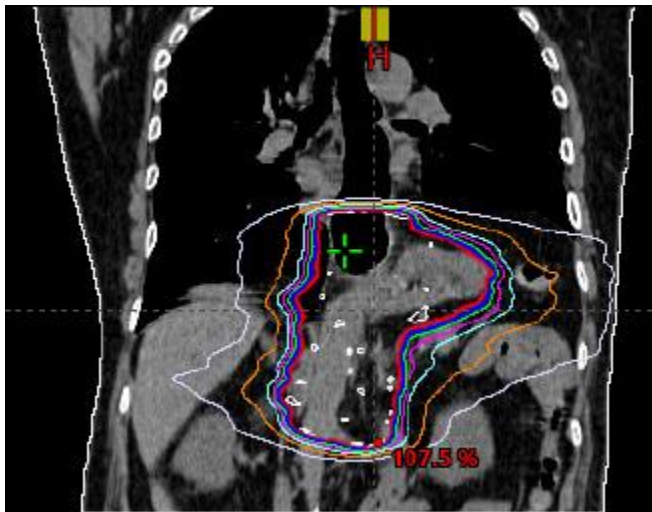
Total Dose (cGy): 1,620

Start Date: 9/15/2022

End Date: 9/28/2022

Elapsed Days: 13

SUMMARY OF RADIATION TREATMENTS: The patient was treated to the esophagus using a **IMRT** technique. The patient tolerated treatments quite well. The patient had the expected side effects of esophagitis.



Case 1 Answer sheet

Primary Site	C16.0	Grade Clinical	3		
Histology	8140	Grade Pathological	9		
Behavior	3	yp Grade	blank		
Schema Discriminator 1	2	Schema Discriminator 2	blank		
HER 2	0				
Stage Data items					
Clinical T	cT2	Pathological T		yp T	
cT Suffix		pT Suffix		yp T Suffix	
Clinical N	cN1	Pathological N		yp N	
cN Suffix		pN Suffix		yp N Suffix	
Clinical M	cM0	Pathological M		yp M	
Clinical Stage	3	Pathological Stage	gg	yp Stage	
		<i>Grade</i>			
Summary Stage 2018		3			
EOD Primary Tumor		250			
EOD Lymph Regional Nodes		800			
EOD Mets		00			
Radiation					
Phases		I	II	III	
Primary Treatment Volume		50	50	00	
Draining Lymph Nodes		05	05		
Treatment Modality		02	02		
External Beam Planning Technique		05	05		
Dose Per Fraction (cGy)		00180	00180		
Number of Fractions		019	009		
Total Dose (cGy)		03420	1620		
Date RT Started		8/15/22			
Date RT Ended		9/28/22			
# of Phases of RT to this Volume		02			
RT Discontinued Early		01			
Total Dose		5040			

Case 2

74 y/o female with h/o GERD, HTN, HLD, DMII, who presented with difficulty with swallowing x 4 weeks. Pt also c/o chest pressure, choking, coughing, epigastric pain and weight loss. Former smoker. Social etoh. +FHx: Father with esophageal cancer.

Imaging:

2/17/22 @ XXX Hospital:

CT CAP= Tiny 1-2 mm LUL pulmonary nodule, indeterminate. Abrupt circumferential luminal narrowing of lower half of esophagus inferior to the carina, approximately 28 cm from incisors, with 15 mm lobular lesion and an 8 mm nodule at 26 cm from incisors with diffuse nodularity at 32 cm from incisors.

Enlarged periesophageal, up to 1.5 cm, and upper abdominal lymphadenopathy, up to 4.5 cm, suspicious for metastases. No mediastinal or axillary lymphadenopathy. No suspicious lytic or blastic osseous lesions.

2/24/22 @ XXX Hospital:

Upper EUS: Esophageal mucosal changes classified as Barrett's stage C9-M9, per Prague criteria. Findings suspicious for neoplasm. Erythematous mucosa without bleeding found in entire examined stomach.

2/28/22 @ ABC Radiology:

PET/CT= Hypermetabolic lower esophageal cancer with LT supraclavicular, mediastinal and upper abdominal nodal metastases (@ least 15 regional LN mets). Hypermetabolic focus without definite CT correlate overlying mid-esophageal wall.

No evidence for distant metastases.

Pathology:

2/24/22 @ XXX Hospital: Esophagus bx

- a. Esophagus bx @ 35 cm: poorly differentiated carcinoma with ulceration
- b. Esophagus bx @ 33 cm: poorly differentiated carcinoma
- c. Esophagus bx @ 31 cm: poorly differentiated carcinoma with ulceration, focal high grade dysplasia,
- d. Esophagus bx @ 29 cm: poorly differentiated carcinoma with ulceration
- e. Esophagus bx @ 27 cm: glandular mucosa with high grade dysplasia
- f. Esophagus bx @ 25 cm: glandular epithelium with high grade dysplasia.

Oncosight Genpath panel positive for FGFR3>KLF15 gene fusion detected. Negative for ALK, AXL, BRAF, EGFR, FGFR1, MET, NRG1, NTRK1, RET, ROS1.

PD-L1 TPS= 50-60%.

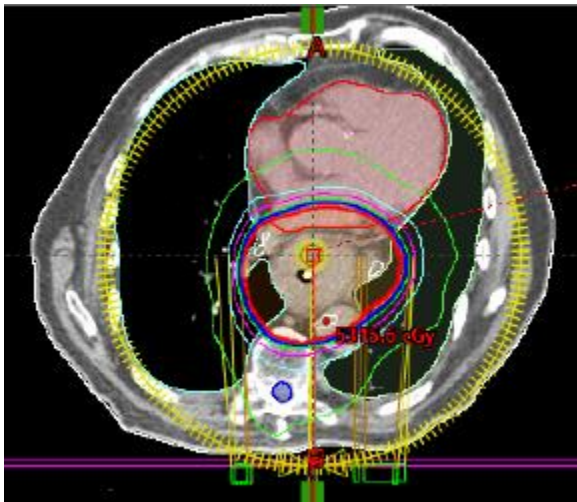
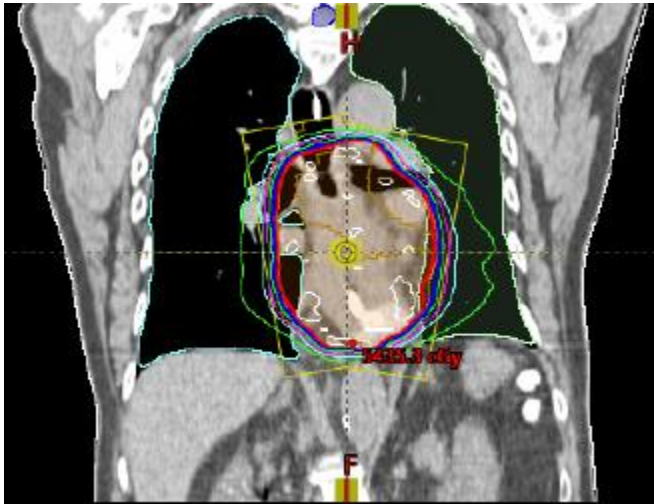
MMR Intact. MSI stable. HER2 IHC= 3+, positive.

Treatment:

3/21/22 @ XXX Hospital: Carboplatin + paclitaxel.

SUMMARY OF RADIATION FIELDS

Treatment Site	Energy Technique	Dose/Fx (cGy)	#Fx	Total Dose (cGy)	Start Date	End Date
Plan_Esophagus_PTV_5040	6X/IMRT	180	28 / 28	5,040	03/21/2022	04/27/2022



Case 2 Answer sheet

Primary Site	C15.5	Grade Clinical	3		
Histology	8010	Grade Pathological	9		
Behavior	3	Grade Post Therapy			
Schema Discriminator 1	Blank	Schema Discriminator 2	Blank		
Her 2	1				
Stage Data items					
Clinical T	Blank	Pathological T	Blank	yp T	
cT Suffix		pT Suffix		yp T Suffix	
Clinical N	cN3	Pathological N	Blank	yp N	
cN Suffix		pN Suffix		yp N Suffix	
Clinical M	cM0	Pathological M	Blank	yp M	
Clinical Stage	4B	Pathological Stage	99	yp Stage	
		<i>Grade</i>			
Summary Stage 2018		7			
<i>EOD Primary Tumor</i>		999			
<i>EOD Lymph Regional Nodes</i>		700			
<i>EOD Mets</i>		00			
Radiation					
Phases		I	II	III	
Primary Treatment Volume		50			
Draining Lymph Nodes		08			
Treatment Modality		02			
External Beam Planning Technique		05			
Dose Per Fraction (cGy)		00180			
Number of Fractions		028			
Total Dose (cGy)		05040			
Date RT Started		3/21/22			
Date RT Ended		4/27/22			
# of Phases of RT to this Volume		01			
RT Discontinued Early		01			
Total Dose		5040			

Case 3:

79 yr-old Caucasian male with h/o HTN, HLD, DMII, COPD, significant smoking hx (30 Pk-Yr), who presented with anemia and chest discomfort. Former etoh abuse (sober since 2010). -fhx.

Scope:

5/16/22 @ XXX Medical Ctr:

Upper EUS= Likely malignant esophageal tumor at GE junction, extending into gastric cardia. Biopsied. Mass found in the GE junction. This was staged T2 N1 by endosonographic criteria using the esophagus staging protocol. In addition, two malignant-appearing lymph nodes were visualized in the perigastric region. FNB performed from the largest node measuring 11 mm.

Imaging:

06/06/22 @ YYY Hospital: CT CAP= Soft tissue thickening within the superior stomach/GE junction, most likely representing pt's known esophageal carcinoma. Adjacent perigastric lymph node noted. Metastatic lymph node not excluded. No evidence of metastatic disease within pelvis.

06/14/22 @ YYY Hospital: PET/CT= Hypermetabolic distal esophageal lesion consistent with esophageal cancer. Abnormal thickening superior stomach and GE junction, SUV max 5.5. Mildly prominent medial perigastric lymph nodes with mild uptake. Could represent inflammation or potentially metastatic lymph node. No other abnormal metabolic activity noted.

Pathology:

5/16/22 @ XXX Medical Ctr:

- a. GE Junction bx= invasive moderately differentiated adenocarcinoma with mucinous features.
- b. Peri-gastric lymph node FNB= metastatic moderately differentiated adenocarcinoma.
HER2 IHC= 1+, negative. MMR panel intact.

5/16/22 @ XXX Medical Ctr:

- Peri-gastric lymph node Ultrasound-guided FNA= positive for malignancy. Metastatic adenocarcinoma. Cytologic findings correlate with patient's concurrent pathologic specimen.

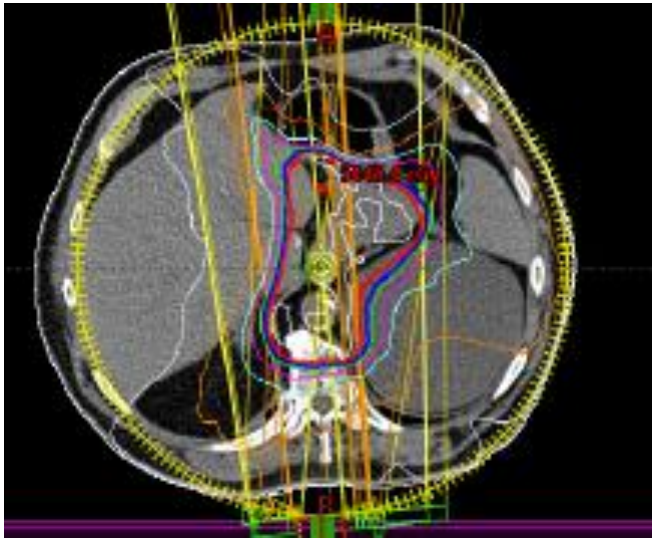
Treatment:

07/22/22 @ XXX Hospital: Carboplatin + paclitaxel weekly x 8 cycles.

Radiation Therapy Treatment Summary @ XXX Hospital:

SUMMARY OF RADIATION FIELDS

Treatment Site	Energy Technique	Dose/Fx (cGy)	#Fx	Total Dose (cGy)	Start Date	End Date
Plan_Esophagus_PTV_5040	6X/IMRT	180	28 / 28	5,040	07/22/2022	08/30/2022



Case 3 Answer sheet

Primary Site	C16.0	Grade Clinical	2		
Histology	8140	Grade Pathological	9		
Behavior	3	Grade Post Therapy			
Schema Discriminator 1	2	Schema Discriminator 2	blank		
Her 2	0				
Stage Data items					
Clinical T	cT2	Pathological T		yp T	
cT Suffix		pT Suffix		yp T Suffix	
Clinical N	cN1	Pathological N		yp N	
cN Suffix		pN Suffix		yp N Suffix	
Clinical M	cM0	Pathological M		yp M	
Clinical Stage	3	Pathological Stage	gg	yp Stage	
		<i>Grade</i>			
Summary Stage 2018		3			
<i>EOD Primary Tumor</i>		250			
<i>EOD Lymph Regional Nodes</i>		300			
<i>EOD Mets</i>		00			
Radiation					
Phases		I	II	III	
Primary Treatment Volume		50	00		
Draining Lymph Nodes		05			
Treatment Modality		02			
External Beam Planning Technique		05			
Dose Per Fraction (cGy)		00180			
Number of Fractions		0			
Total Dose (cGy)		05040			
Date RT Started		7/22/22			
Date RT Ended		8/30/22			
# of Phases of RT to this Volume		01			
RT Discontinued Early		01			
Total Dose		5040			

Case 4:

45 y/o Caucasian male who presented to his PCP with hoarseness, dysphagia and chest pressure when eating. Patient reports a 15 lb weight loss in past 3 months. Former smoker. Social etoh. +fhx: father w/ prostate cancer at 74.

Pt opted for neoadjuvant chemo/RT, followed by surgery.

Scope:

4/5/22 @ YYY Hospital:

Upper EUS: Submucosal mass @ GEJ extending into the gastric cardia at the proximal lesser curvature. Mass extends from 43 to 47 cm. Mass is not obstructing. Sonographically, T3, N0.

Imaging:

4/11/22 @ YYY Hospital:

CT CAP= Non-specific small right upper lobe reticulonodular densities, likely infectious/inflammatory in etiology. No mediastinal lymphadenopathy noted. Recommend CT f/u in 3 months.

Non-specific mild thickening of the gastroesophageal junction in the region of clinically known lesion. No evidence of metastatic disease. No evidence of significant retroperitoneal or pelvic lymphadenopathy.

Pathology:

4/5/22 @ YYY Hospital: EG Junction bx; adenocarcinoma. Reviewed @ XXX Hospital on 4/10/22, which read specimen as moderately to poorly differentiated adenocarcinoma.

8/9/22 @ XXX Hospital: Laparoscopic esophagectomy with regional lymph node dissection.

- foci of residual adenocarcinoma invading esophageal wall and paraesophageal fat.
- LVI negative.
- Regional lymph nodes examined= 22
- Regional lymph nodes with micromets= 0
- Regional lymph nodes with macromets= 0.

Treatment:

4/26/22 @ XXX Hospital: Carboplatin + paclitaxel x 8 cycles.

Radiation Therapy Treatment Summary @ XXX Hospital:

SUMMARY OF RADIATION FIELDS

Treatment Site	Energy Technique	Dose/Fx (cGy)	#Fx	Total Dose (cGy)	Start Date	End Date
Plan_Esophagus_PTV_5040	6X/IMRT	180	28 / 28	5,040	04/26/2022	05/02/2022

Case 4 Answer sheet

Primary Site	C16.0	Grade Clinical	3		
Histology	8140	Grade Pathological	9		
Behavior	3	Grade Pathological Post Therapy	9		
Schema Discriminator 1	2	Schema Discriminator 2	blank		
Stage Data items					
Clinical T	cT3	Pathological T		yp T	ypT3
cT Suffix		pT Suffix		yp T Suffix	
Clinical N	cN0	Pathological N		yp N	ypN0
cN Suffix		pN Suffix		yp N Suffix	
Clinical M	cM0	Pathological M		yp M	cM0
Clinical Stage	3	Pathological Stage	99	yp Stage	2
		<i>Grade</i>			

Summary Stage 2018	2
<i>EOD Primary Tumor</i>	300
<i>EOD Lymph Regional Nodes</i>	000
<i>EOD Mets</i>	00

Radiation			
Phases	I	II	III
Primary Treatment Volume	50	00	
Draining Lymph Nodes	00		
Treatment Modality	02		
External Beam Planning Technique	05		
Dose Per Fraction (cGy)	00180		
Number of Fractions	0		
Total Dose (cGy)	05040		
Date RT Started	4/26/22		
Date RT Ended	5/2/22		
# of Phases of RT to this Volume	01		
RT Discontinued Early	01		
Total Dose	5040		